

---

**ORIGINAL ARTICLE****Lumbosacral Transitional Vertebra-Prevalence of Different Types in South Indian Population with Low Backache**

V. Sivakumar<sup>1</sup>, C. Poonam<sup>2</sup>, D. Ethiraj<sup>3</sup>, I. Venkatraman<sup>2\*</sup>

<sup>1</sup>Department of Radiodiagnosis, Meenakshi Medical College and Research Institute, Kancheepuram-631552 (Tamilnadu) India, <sup>2</sup>Department of Radiodiagnosis, Sree Balaji Medical College and Hospital, Chromepet, Chennai – 600044 (Tamilnadu) India, <sup>3</sup>Department of Radio-diagnosis, Bharath Medical College and Hospital, Selaiyur, Chennai-600073 (Tamilnadu) India

---

**Abstract:**

**Background:** Lumbosacral transitional vertebrae are common congenital anomaly of the spine involving the lumbosacral vertebral junction with a prevalence of 4-35.9%. It can present as sacralization of the lowermost lumbar vertebra or lumbarization of the first sacral vertebra with varying degree of transition from partial to complete fusion. Non-recognition of this variant and/or poor description in the report can lead to operations or procedures performed at the wrong level. **Aim and Objectives:** The purpose of this descriptive cross-sectional study is to determine the prevalence and frequency of different types of Lumbosacral Transitional Vertebra (LSTV) in patients with low back pain in South Indian population. **Material and Methods:** Plain radiographs of the lumbosacral spine of 450 patients who presented with lower back pain were retrospectively reviewed for the presence and type of LSTV. **Results:** Using Castellvi system, 450 patients were evaluated and LSTV was observed in 126 patients (28%). Among them 51 (40%) patients had type I, 42 (33.3%) had type II, 27 (21.4%) had type III and 6 (4.7%) had type IV. **Conclusion:** LSTV occurs at a high frequency in patients with LBP in South Indian population.

**Keywords:** Castellvi Classification, Lumbarization, Lumbosacral Transitional Vertebra, Plain Radiographs, Sacralization

**Introduction:**

Lumbosacral Transitional Vertebrae (LSTV) are a relatively common congenital anomaly of lumbosacral junction and has morphologic characteristics mixed between those of sacral and lumbar vertebrae [1-2]. They can present as a lumbarized S1 segment (assimilation of S1 to lumbar spine) or sacralized L5 segment (fusion of elongated and broadened transverse process of L5 segment with sacrum) [1, 3]. There can be a varying degree of transition, from partial (pseudo-arthrosis) to complete fusion and can be unilateral or bilateral. Even though lumbosacral Anteroposterior (AP) radiographs and abdominal radiographs are commonly used, Computed Tomography (CT) and Magnetic Resonance Imaging (MRI) can also be used for evaluation of these lumbosacral anomalies. Accurate recognition of this variant is important to prevent surgical procedures being performed at wrong levels as this modification can lead to incorrect determination of vertebral segment.

Bertolotti was first to describe the morphologic characteristics of LSTV and its association with low back pain in 1917 and this association is known as Bertolotti syndrome [4-5]. Depending on the location of pain various etiopathogenesis have been

**Table 1: Castellvi Radiographic Classification of Lumbosacral Transitional Vertebrae**

Definition	Castellvi type
Enlarged and dysplastic transverse process (with height/craniocaudal distance more than 19 mm)	Type I- A: Unilateral B: Bilateral
Incomplete lumbarization/sacralization due to pseudo-articulation of the enlarged transverse process and adjacent sacrum alae	Type II - A: Unilateral B: Bilateral
Complete lumbarization or sacralization due to complete bony fusion of enlarged transverse process with the adjacent sacral alae	Type III - A: Unilateral B: Bilateral
Type II on one side and type III on the contralateral side	Type IV- Mixed type

proposed for describing low back pain associated with LSTV. Pain may arise from anomalous articulation, level above the transition or the contralateral facet. Castellvi established the X-ray classification of LSTV (Table 1). Scarce data exist on the prevalence of sacralisation and frequency of its various types in South Indian population. Aim of the study was to find out the general prevalence of LSTV in patients with low back pain in South Indian population and frequencies of its types according to Castellvi classification.

#### Material and Methods:

In this descriptive cross-sectional study, we retrospectively reviewed the findings of radiography of 450 patients performed from 1<sup>st</sup> October 2019 to 31<sup>st</sup> March 2020 in the Department of Radio-diagnosis, Meenakshi Medical College, Hospital and Research Institute, Kanchipuram, Tamil Nadu. All patients aged 11–90 years of either gender from the states of Tamil Nadu, Karnataka, Andhra Pradesh, Telangana and Kerala who presented with lower back pain for any duration and underwent X-ray of the lumbosacral spine were included in this study. Exclusion criteria included patients with a history of traumatic injury

to the spine or vertebral column, infectious diseases involving the spine and a history of spinal surgery. Individuals from other parts of India (other than the South Indian states mentioned above) were excluded from the study.

The requirement of informed consent was waived as the data were retrieved from Picture Archiving and Communication System (PACS). The parameter used for identifying the presence of LSTV was the width of the bilateral transverse processes of L5 lumbar vertebra as measured on AP lumbosacral spine X-rays. If present the LSTV was further classified using Castellvi radiographic classification into four types.

#### Radiograph Procedure:

Plain radiographs of the lumbosacral spine in AP view were acquired. Even though traditionally Ferguson view (AP lumbar spine radiograph with 30° cranial angulation) and lateral projection radiographs were used as the best method for identification of lumbosacral transitional vertebra, recently it has been largely replaced by cross-sectional imaging with CT being the best imaging technique. But identification of this anomaly on CT is usually an incidental finding as CT is not

recommended for identification of LSTVs as there is risk of radiation exposure, also it is not the initial imaging modality of choice for non-traumatic low back pain. Radiographs were obtained by digital radiography using a computed radiography system (Fuji Medical Systems, USA Inc., Stamford, CT, USA) with exposure settings of 60–90 kV and 30 mAs. Plain radiographs were interpreted and analyzed by two radiologists with an experience of more than 8 years and classified according to Castellvi radiographic classification system.

**Data Analysis:**

SPSS software version 22 (IBM Corp., Armonk, NY, USA) was used for statistical analysis. Demographic data of the patient (age and sex), bilateral cranio-caudal measurement of the lowest lumbar transverse processes, the presence of LSTV in the plain radiography images and its type was recorded. Age of the patient was used to calculate the Mean and Standard Deviation (SD)

(continuous variables). Whereas age categorization (<20 years, 20–40 years, and >40 years), sex, and the presence of lumbosacral transitional vertebrae on X-ray were used to calculate the frequency and percentages (categorical variables). Unpaired t test and one-way analysis of variance were used to evaluate the continuous variables while the chi-square and Fisher's exact test were applied to evaluate the categorical variables with p-value <0.05 considered to be significant.

**Results:**

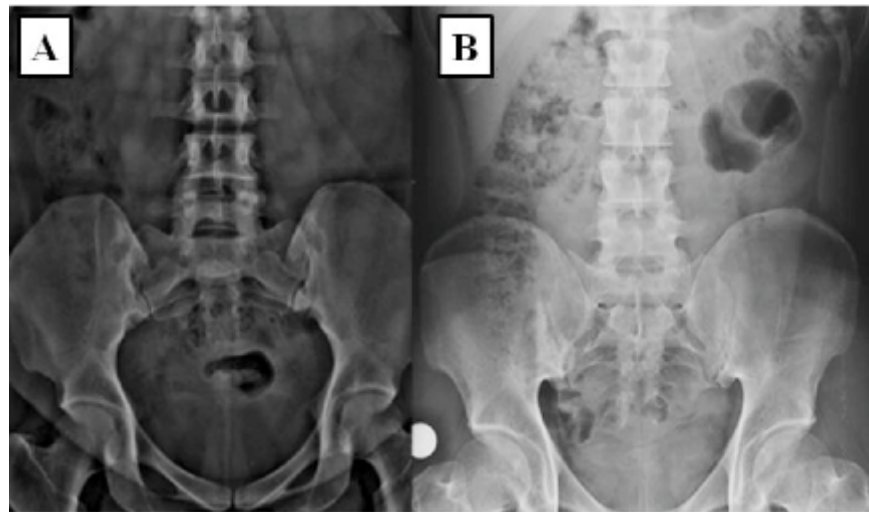
Plain radiographs of 450 patients were included in the study with patient's age ranging from 15-88 years and mean age being 45.31 ± 12.3 years. Among them patients older than 40 years constituted the largest subgroup followed by patients in age range of 20-40 and only 10 patients younger than 20 years. Of the total 450 patients 248 (55%) were males and 202 (45%) females with male to female ratio of 1.2:1 (Table 2).

**Table 2: LSTVs in Different Age Groups and Sex with Frequency and Percentages of Cases according to Castellvi Classification**

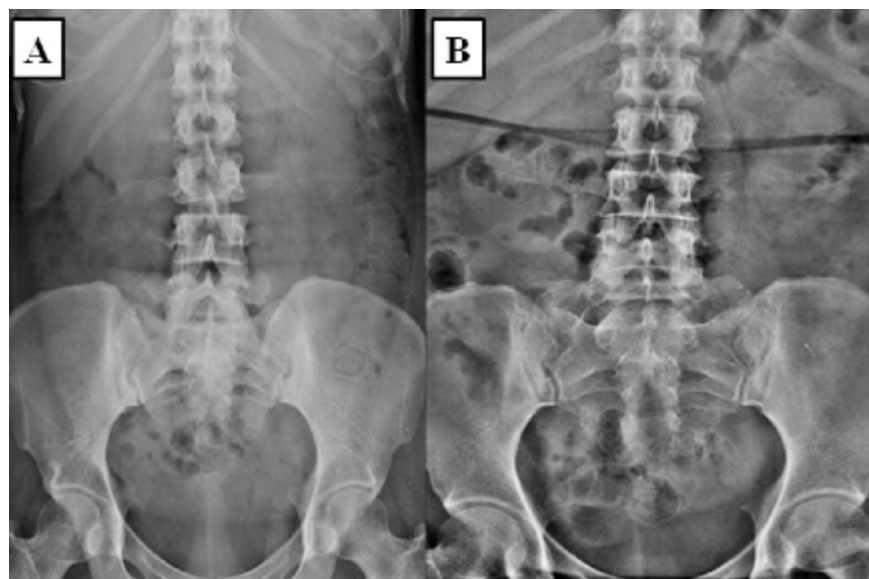
Percentage (%)	Frequency	Castellvi Type	Total	Gender		Age >40 years	Age 20-40 years	Age <20 years	Type
				Males	Females				
23.8	30	IA	51	29	22	27	20	4	I
16.6	21	IB							
16.6	21	IIA	42	23	19	26	13	3	II
16.6	21	IIB							
9.5	12	IIIA	27	16	11	15	10	2	III
11.9	15	IIIB							
4.7	6	IV	6	4	2	3	2	1	IV

Out of the total patients (N=450) only a few (n=126, 28%) were positive for LSTV and majority (n=324, 72%) were normal (Fig. 1) as revealed by X-ray analysis. One hundred twenty six patients positive for LSTV were further classified based on the Castellvi classification system and Castellvi type I (Fig. 2) was seen in 51 (40.5%), type II (Fig.

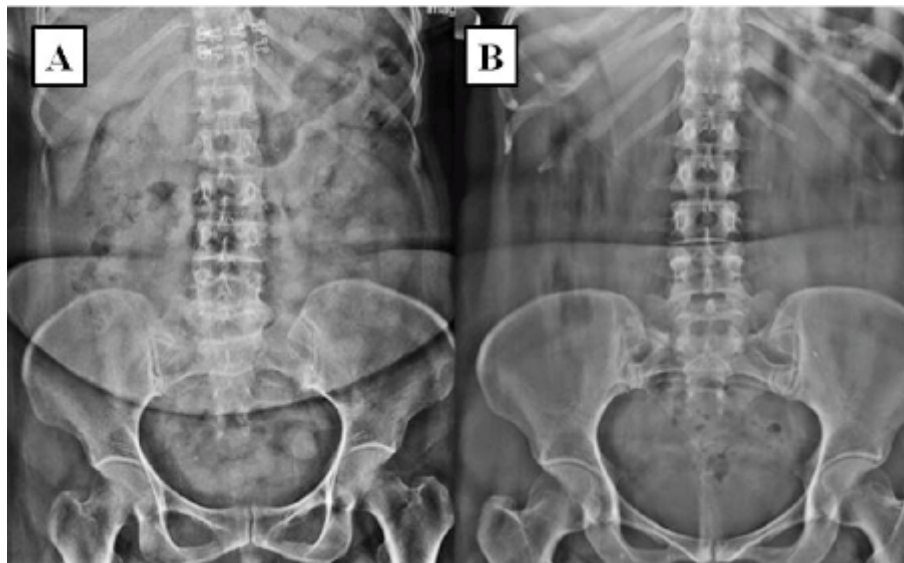
3) in 42 (33.3%), type III (Fig. 4) in 27 (21.4%) and type IV (Fig. 5) in 6 (4.7%) patients. Further subdivision with their frequencies and percentages is given in Table 2. Two patients had type IIA on one side and IA on the other side - these two patients were considered under IIA for statistical purposes.



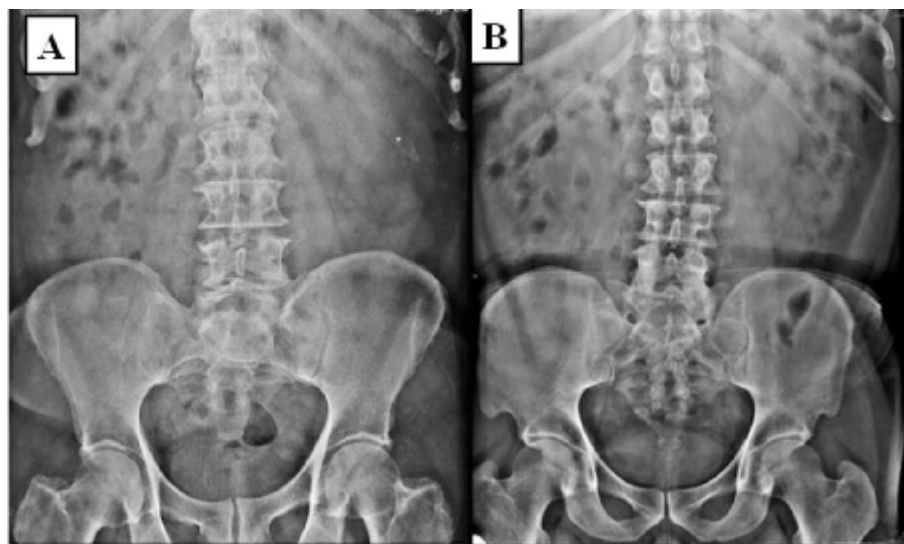
**Fig. 1: Lumbosacral AP Radiographs (A and B):** showing normal transverse processes of L5 vertebra and normal S1 vertebra.



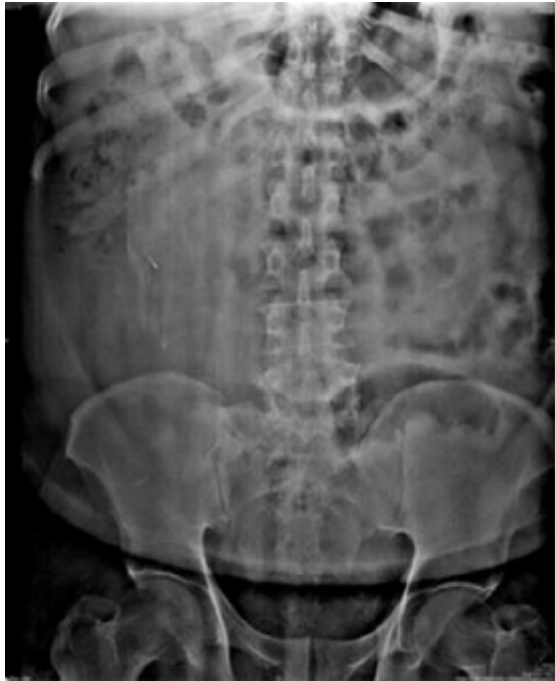**Fig. 2: Lumbosacral AP Radiographs:** showing dysplastic and enlarged transverse process of L5 vertebra on left side (A)-type IA and bilaterally (B)-type IB.



**Fig. 3: Lumbosacral AP Radiographs:** showing pseudo-articulation of the enlarged transverse process and adjacent sacrum on right side (A)-type IIA and bilaterally (B)-type IIB.



**Fig. 4: Lumbosacral AP Radiographs:** showing complete articulation of enlarged transverse process with the adjacent sacral alae on left side (A)-type IIIA and bilaterally (B)-type IIIB.



**Fig. 5: Lumbosacral AP Radiograph:** showing pseudo-articulation of an enlarged transverse process and adjacent sacrum on left side and complete articulation of an enlarged transverse process with the adjacent sacral ala on right side-Type IV.

#### Discussion:

LSTV is a common congenital anomaly of the lumbosacral junction with prevalence of 4% to 35.9%. It arises because of mutations in the Hox genes which are responsible for vertebral column segmentation into individual vertebral segments [1]. This genetic etiology is attributed for its wide variation in the prevalence along with other factors like type of study population, criteria and classification system used, imaging modality considered at the time of study. Prevalence of LSTV in Indian population was found to be around 16%. A study conducted by Daniel *et al.* in Punjabi population showed a prevalence of 22% with maximum frequency of Type IIA [7]. Our

study which was conducted in South Indian population showed a prevalence of 28% and maximum frequency of Type IA. Various studies have been conducted in various populations using different imaging modalities and classification systems and have concluded variable prevalence of LSTV. A study conducted by Hsieh *et al.* in primarily Chinese population showed a prevalence of 4% using AP plain radiographs for diagnosis and Erken *et al.* found a prevalence of 35.9% using AP plain radiographs. Castellvi type I LSTV was included in a few studies like Nardo *et al.*, Erken *et al.*, Uçar *et al.* but was excluded from studies like Hsieh *et al.*, Sekharappa *et al.* and French *et al.* [3-5]. Some studies conducted in population with low back pain showed a higher prevalence of LSTV than found in general population while other studies showed no correlation between them [4, 8-11]. A high prevalence of LSTV was found in male patients in the present study conducted in South Indian population presenting with low back ache diagnosed using AP plain radiographs. Maximum frequency of LSTV was found to be of type IA while type IV had least frequency.

LSTV is responsible for disruption of normal biomechanics and anatomy of spine. The lumbosacral spine plays a crucial role in posture, locomotion and transmission of upper body weight to Sacro-iliac (SI) joints. The dissipation of load by sacrum depends on its size and its surface area with the SI joint. Mutation of HOX gene is responsible for formation of transitional vertebrae which can also be influenced by functional requirements of load transmission at the SI junction. Depending on the load bearing capacity of the sacrum, the process of addition or diminution of segments to or from the sacrum

takes place at an early stage of development. Incorporation of L5 into S1 takes place if the sacrum is small with insufficient surface area with S1 joint while S1 is released in a sacrum with over-competent load bearing capacity [12]. LSTVs can exhibit morphological abnormality and/or numerical variance. The morphological abnormalities of LSTV are classified using system described by Castellvi *et al.* (Table 1) which is widely accepted because of its simplicity [2, 13]. Squaring of the upper sacral segment in lumbarisation and wedging of the lowest lumbar segment in sacralisation are other morphological characteristics of transitional vertebrae. Accurate assignment of spinal segments is crucial for correct patient management and can be done by various imaging modalities. On AP and lateral lumbosacral radiographs, LSTV can be identified based on the articulation of the last rib with the T12 vertebra as described by Bron *et al.* [7, 14]. MRI can also be used for vertebral segment assignment by identifying iliolumbar ligament which in 96% of people attaches to transverse process of L5 and by assessing the position of the right renal artery which lies adjacent to L1/L2 disc space [7, 15]. As described by a study conducted by Nicholson *et al.*, the intervertebral disk height between L5 and S1 decreases in presence of LSTV as compared with normal. It has also been observed that the disk space between S1 and S2 is larger in presence of lumbarised S1 as compared to spines without transitional segments [19, 21].

#### **Clinical Significance: Bertolotti Syndrome**

Mario Bertolotti was the first to describe low back pain in presence of LSTV in 1917 and this association is known as Bertolotti syndrome [1, 16-18]. Although this association has been debated

over a century since Bertolotti first described it and is still controversial. Various studies have shown a prevalence of LSTV in patients seeking care for low back pain ranging from 4.6%-35.6% [12, 18-19]. Various etiopathogenesis for the pain associated with LSTV have been proposed depending on the location of origin 1) disc herniation or degeneration, facet joint arthrosis, or spinal canal or foraminal stenosis. 2) Pseudo articulation between lowest lumbar transverse process and sacrum leading to a false joint and causing localized stress and low back pain. 3) Arthritic changes occurring at the site of pseudoarthrosis. 4) Disc protrusion or extrusion above the transitional vertebra leading to radiating pain as a result of nerve root compression. Transitional vertebra of Castellvi types II-IV were implicated in most studies supporting Bertolotti syndrome and Castellvi type I was considered a normal variant when Bertolotti first described LSTVs and its association with low back pain.

#### **Treatment:**

LSTV though common, its association with low back pain is still controversial. Various treatment options have been proposed and consist of both conservative as well as surgical management. Local injection of anaesthetic and corticosteroids into the transverse process and sacral articulation site (pseudo articulation) or contralateral facet joint radio-frequency ablation are few conservative or non-surgical treatment options. These local injections serve both diagnostic and therapeutic purpose in patients posted for surgical management. [17-18]. Partial transverse process resection, and/or posterior spinal fusion, laminectomy and surgical nerve decompression are the surgical treatments of choice. Surgical

management is usually suggested as the last resort if the conservative management fails. The choice of surgical intervention depends on the pathogenesis of pain. If degenerated disk above the transitional vertebra is the source of pain then posterior spinal fusion can be done. In cases with contralateral facetogenic pain, resection of the ipsilateral anomalous articulation has shown successful relief [20].

#### Limitations:

Convenience sampling and studying the prevalence of LSTV in those who underwent spinal radiographs for low back pain, rather than looking for its prevalence in general population is one of the limitations of the study. The other limitation is that the study is conducted in a city with mixed population of geographical origin, though we have tried to address it by excluding those from states

other than Tamil Nadu, Karnataka, Andhra Pradesh, Telangana and Kerala. This data could be used for comparison later with a study for the prevalence of LSTV in general population.

#### Conclusion:

LSTVs were found to be occurring at a variable frequency in various populations and geographical areas. Our study showed a high frequency in patients with low back pain in the South Indian population and most common being Castellvi type IA. It is a common anomaly of the lumbosacral spine whose identification and accurate enumeration of vertebral segment is crucial to avoid unanticipated outcomes during surgical interventions. Although the association of low back pain with LSTV is still controversial there is fairly convincing evidence for a higher prevalence of LSTVs in population with low back pain.

#### References

1. Bhattarai M. A hospital based plain radiographic observational study of lumbosacral transitional vertebrae in the Nepalese population. *Asian J Med Sci* 2018; 9(4):46-50.
2. Hou L, Bai X, Li H, Gao T, Li W, Wen T, et al. Lumbar plain radiograph is not reliable to identify lumbosacral transitional vertebra types according to Castellvi classification principle. *BMC Musculoskelet Disord* 2020; 21: 333.
3. Uçar D, Uçar BY, Coşar Y, Emrem K, Gümüştuyu G, Mutlu S, et al. Retrospective cohort study of the prevalence of lumbosacral transitional vertebra in a wide and well-represented population. *Arthritis* 2013; 2013: 461425.
4. Nardo L, Alizai H, Virayavanich W, Liu F, Hernandez A, Lynch JA, et al. Lumbosacral transitional vertebrae: association with low back pain. *Radiology* 2012; (265):497-503.
5. Sekharappa V, Amritan and R, Krishnan V, David KS. Lumbosacral transition vertebra: prevalence and its significance. *Asian Spine J* 2014;8(1):51-58.
6. Shaikh A, Khan SA, Hussain M, Soomro S, Adel H, Adil SO, et al. Prevalence of lumbosacral transitional vertebra in individuals with low back pain: evaluation using plain radiography and magnetic resonance imaging. *Asian Spine J* 2017; 11(6):892-897.
7. Daniel P, Joel JJ, Rana PK. Lumbosacral transitional vertebrae in patients with low back pain: Radiological classification and morphometric analysis. *J Anat Soc India* 2019;(68):123-8
8. Dai L. Lumbosacral transitional vertebrae and low back pain. *Bull Hosp Jt Dis* 1999; 58(4):191-193.
9. Oyinloye OI, Abdulkadir AY, Babalola OM. Incidence and patterns of lumbosacral transitional vertebrae, in patients with low backpain in a Nigerian hospital. *Nig Q J Hosp Med* 2009;19(2):95-99.
10. Luoma K, Vehmas T, Raininko R, Luukkonen R, Riihimäki H. Lumbosacral transitional vertebra: relation to disc degeneration and low back pain. *Spine (Phila Pa 1976)* 2004;29(2):200-205.
11. Tini PG, Wieser C, Zinn WM. The transitional vertebra of the lumbosacral spine: its radiological classification, incidence, prevalence, and clinical significance. *Rheumatol Rehabil* 1977;16(3):180-185



12. Jancuska JM, Spivak JM, Bendo JA. A Review of Symptomatic Lumbosacral Transitional Vertebrae: Bertolotti's Syndrome. *Int J Spine Surg* 2015; 9:42.
13. Castellvi AE, Goldstein LA, Chan DP. Lumbosacral transitional vertebrae and their relationship with lumbar extradural defects. *Spine (Phila Pa 1976)* 1984;9(5):493-495.
14. Bron JL, van Royen BJ, Wuisman PI. The clinical significance of lumbosacral transitional anomalies. *Acta Orthop Belg* 2007; 73(6):687-695.
15. Hughes RJ, Saifuddin A. Imaging of lumbosacral transitional vertebrae. *Clin Radiol* 2004; 59(11):984-991.
16. Bertolotti M. Contributo alla conoscenza e i vizi differenziazione regionale del rachide con special riguardo all assimilazione sacrale della V. *Lombare Radiol Med* 1917;(4):113-144
17. Holm EK, Büniger C, Foldager CB. Symptomatic lumbosacral transitional vertebra: a review of the current literature and clinical outcomes following steroid injection or surgical intervention. *SICOT J* 2017; 3:71.
18. Jadon A. Bertolotti's Syndrome and Its Management; Pain Physician Perspective-A Brief Review. *Clin Surg* 2017; (2): 1737
19. Konin GP, Walz DM. Lumbosacral transitional vertebrae: classification, imaging findings, and clinical relevance. *AJNR Am J Neuroradiol* 2010;31(10):1778-1786.
20. Brault JS, Smith J, Currier BL. Partial lumbosacral transitional vertebra resection for contralateral facetogenic pain. *Spine (Phila Pa 1976)* 2001; 26(2):226-229.
21. Nicholson AA, Roberts GM, Williams LA. The measured height of the lumbosacral disc in patients with and without transitional vertebrae. *Br J Radiol* 1988; 61(726):454-455.

**\*Author for Correspondence:**

Dr. I. Venkatraman, Department of Radiodiagnosis,  
Sree Balaji Medical College and Hospital, Chromepet,  
Chennai – 600044 (Tamilnadu) India  
Email:ivraman31@gmail.com Cell:9443067358

**How to cite this article:**

V. Sivakumar, C. Poonam, D. Ethiraj, I. Venkatraman.  
Lumbosacral Transitional Vertebra-Prevalence of  
Different Types in South Indian Population with Low  
Backache. *J Krishna Inst Med Sci Univ* 2021; 10(2):  
76-84

Submitted: 03-Nov-2020 Accepted: 01-Jan-2021 Published: 01-Apr-2021